

Clinical Outcomes Following Implantation of A New Aspheric Monofocal Intraocular Lens

Yeni Asferik Monofokal Göz İçi Lensin İmplantasyonun Takiben Klinik Sonuçları

Ulviye Yiğit , Ercan Çavuşoğlu , İ. Umut Onur , F. Selin Kaya 

Department of Eye Diseases, University of Health Sciences Bakırköy Dr. Sadi Konuk Research and Training Hospital, İstanbul, Turkey

Cite this article as: Yiğit U, Çavuşoğlu E, Onur İU, Kaya FS. Clinical Outcomes Following Implantation of A New Aspheric Monofocal Intraocular Lens. JAREM 2019; DOI: 10.5152/jarem.2019.2355

ABSTRACT

Objective: This study aims to know if patients implanted with the OPTIFLEX Natural Yellow Hydrophilic Aspheric IOL (Moss Vision Inc. Ltd, London, UK) achieved the desired refractive outcome, with reduced reliance on spectacle correction and no significant decline in contrast or inducement/change in spherical aberrations.

Methods: This study is a single-center retrospective study in patients with cataract. Medical records of patients who were followed up for 6 months were reviewed. Data on distance, intermediate and near visual acuity, refractive error (sphere, cylinder, and manifest spherical equivalent [MSE]), contrast sensitivity, and adverse events were collected and analyzed.

Results: A total of 48 eyes of 48 patients, with mean age of 66.84±9.72 years (range, 43–88 years) and equal distribution of both genders, were included in the present study. Mean preoperative uncorrected distance visual acuity (UDVA) was 0.81±0.30 LogMAR, and mean UDVA was improved to 0.17±0.15 LogMAR at 6 months follow-up ($p<0.001$). Mean corrected distance visual acuity (CDVA) was improved to 0.06±0.12 LogMAR at 6 months follow-up ($p<0.001$). Mean uncorrected intermediate visual acuity (UIVA) and mean uncorrected near visual acuity (UNVA) at 6 months follow-up were 0.30±0.15 LogMAR and 0.31±0.16 LogMAR, respectively. There was statistically no significant change from the preoperative values ($p>0.05$) in mean refractive spherical equivalent at follow-up visits. An adverse event of diabetic retinopathy, which was nonserious, mild in nature, and unrelated to the study device and index procedure, was reported in one patient.

Conclusion: The OPTIFLEX Natural Yellow Hydrophilic Aspheric IOL improved visual acuity outcomes in patients who underwent cataract surgery, without any complications, while preserving visual quality.

Keywords: Aspheric monofocal intraocular lens, aberration-free aspheric monofocal intraocular lens, cataract surgery, intraocular lens, monofocal intraocular lens

ÖZ

Amaç: Bu çalışmanın amacı, aberasyon oluşturmayan "OPTIFLEX Natural Yellow Hydrophilic Aspheric IOL (Moss Vision Inc Ltd, London, UK)" implante edilen hastalarda arzu edilen refraktif sonuçlara ne ölçüde ulaşıldığını, gözlük kullanımına gereksinim miktarını, kontrast duyarlılıkta veya sferik aberasyonlarda değişiklik olup olmadığını değerlendirmektir.

Yöntemler: Çalışma, kataraktlı hastalarda yapılmış tek merkezli retrospektif bir çalışmadır. 6 aylık takip süresini tamamlayan hastaların kayıtları değerlendirildi. Uzak, orta ve yakın görme keskinliği, refraktif hata (sferik, silindirik ve sferik eşdeğer), kontrast duyarlılık ve yan etki verileri toplandı ve analiz edildi.

Bulgular: 48 hastanın 48 gözünü kapsayan çalışmamızda ortalama yaş 66,84±9,72 (43-88 aralığında) ve cinsiyet bakımından kadın-erkek oranı eşitti. Ameliyat öncesi 0,81±0,30 LogMAR olarak saptanan ortalama düzeltilmemiş uzak görme keskinliği (UDVA); 6.ayda 0,17±0,15 LogMAR olarak bulundu ($p<0,001$). Ortalama düzeltilmiş uzak görme keskinliği (CDVA) ise 6 aylık takipte 0,06±0,12 LogMAR artış gösterdi ($p<0,001$). Ortalama düzeltilmemiş ara mesafe görme keskinliği (UIVA), ortalama düzeltilmemiş yakın görme keskinliği (UNVA) 6 aylık takiplerde sırasıyla 0,30±0,15 LogMAR ve 0,31±0,16 LogMAR dı. Ortalama refraktif sferik eşdeğer açısından, takip vizitlerde ameliyat öncesi değerlere göre anlamlı fark gözlenmedi ($p>0,05$). Olumsuz olarak bir hastada ciddi olmayan, hafif ve çalışma malzemelerine bağlı olmayan diabetik retinopati gözlemlendi.

Sonuç: Katarakt ameliyatlı hastalarda "OPTIFLEX Natural Yellow Hydrophilic Aspheric IOL" e bağlı hiçbir komplikasyon görülmezsizin, görme kalitesi korunarak görme keskinliği artırılmıştır.

Anahtar kelimeler: Asferik monofokal göz içi lense, aberasyon oluşturmayan asferik monofokal göz içi lense, göz içi lense, monofokal göz içi lense, katarakt cerrahisi



INTRODUCTION

Visual quality and acuity outcomes following cataract surgery have greatly improved over the past few decades, owing primarily to the advancements in intraocular lens (IOL) designs (1). The development of new technologies that better identify the likelihood of a patient experiencing annoying visual obscurations due to higher-order aberrations (HOAs) has been significant in shaping this shift in IOL technology (2). Indeed, while IOLs with spherical optics were initially preferred for cataract surgery, increased awareness about their ability to contribute to postoperative degradation of visual quality has led to the creation of aspheric IOLs. As the first aspheric IOL introduced onto the market, the Tecnis Aspheric IOL (Abbott Medical Optics, Santa Ana, CA) paved the way for this shift in IOL technology. Contrary to spherical IOLs that added more positive spherical aberration to the lens, thus worsening visual quality after IOL implantation, aspheric IOLs focus on either adding negative spherical aberration to cancel out the positive or not adding any spherical aberration to the lens at all. The existing literature shows that IOL implantation is considered a safe, effective, and predictable procedure for replacing a cataractous lens, regardless of the type of IOL optics – spherical or aspheric. However, analysis of the visual outcomes achievable with both IOL types suggests that although there is a slight difference between spherical and aspheric IOLs in terms of visual acuity, the latter appears to deliver better contrast sensitivity results, especially under low light (1). Published studies by Denoyer et al. and Trueb et al. among others, have provided results that support the claims that aspheric IOLs can significantly improve the quality of vision and increase contrast sensitivity (3-8).

This study aims to know if patients implanted with the OPTIFLEX Natural Yellow Hydrophilic Aspheric IOL achieved the desired refractive outcome, with reduced reliance on spectacle correction and no significant decline in contrast or inducement/change in spherical aberrations.

METHODS

This study is a single-center retrospective study which investigates the visual outcomes of eyes implanted with the Optiflex MOFNA01 (Figure 1), which is performed by a single surgeon (U.Y.). This study was conducted in accordance with the Declaration of Helsinki, Good Clinical Practices, and International Organization for Standardization 14155: 2011. The study protocol was approved by the Ethical Committee of Bakırköy Dr. Sadi Konuk Research and Training Hospital, and patients' consents were not

obtained as this is a retrospective analysis; however, all patients who underwent surgery in our clinic were informed that their medical records may be used for scientific purposes.

Data from preoperative and postoperative assessments of patients implanted with the study IOL were collected from electronic medical records and analyzed. All included patients were followed up for 6 months at regular intervals (at 1 week; 1, 3, and 6 months).

Data collected from preoperative assessments included uncorrected distance visual acuity (UDVA) and corrected distance visual acuity (CDVA) tested with ETDRS chart at 4 m, refractive status as sphere, cylinder, and manifest spherical equivalent (MSE; value of the sphere plus one-half of the value of the cylinder), optical biometry, and corneal topography measurements. Biometry was performed using IOLMaster (Carl Zeiss, Germany). Manual immersion biometry (Nidek, Japan) was performed in eyes in which IOLMaster could not be used due to the presence of a dense cataract. The IOL power was calculated using the SRK-T formula (A-constant: 118.5) in eyes with an axial length (AL) of 22 mm to 24 mm. The Hoffer Q formula (pACD=5.61) was used in eyes with a shorter AL (<22 mm) and the Holladay 2 formula (ACD constant=5.607) in eyes with a longer AL (>24 mm).

Postoperative data collected at 1-week and 1-, 3-, and 6-month visits included UDVA and CDVA with ETDRS chart at 4 m, uncorrected near visual acuity (UNVA) and corrected near visual acuity

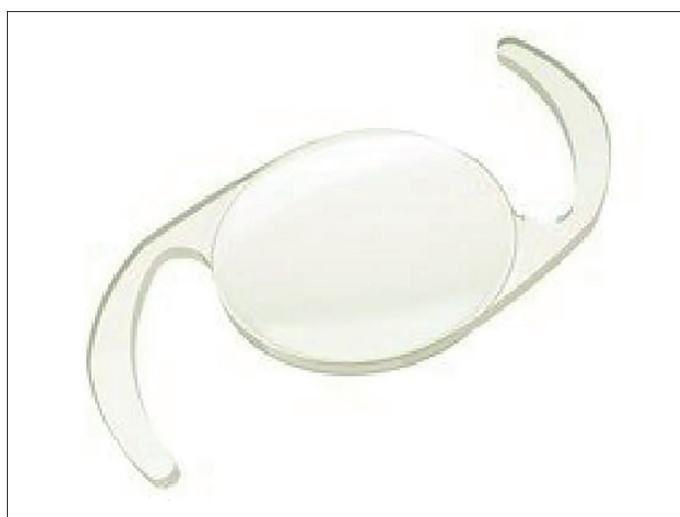

Figure 1. Optiflex MOFNA01 IOL

Table 1. Uncorrected and corrected visual acuity results (LogMAR) (n=48) for the cohort

	UDVA	CDVA	UIVA	CIVA	UNVA	CNVA
Preoperative	0.81±0.33	0.61±0.34				
Postoperative 1 week	0.20±0.22	0.08±0.11	0.42±0.23	0.19±0.19	0.38±0.24	0.04±0.11
Postoperative 1 month	0.18±0.17	0.06±0.08	0.33±0.14	0.12±0.13	0.34±0.16	0.04±0.08
Postoperative 3 months	0.18±0.17	0.07±0.09	0.34±0.13	0.12±0.10	0.35±0.13	0.04±0.07
Postoperative 6 months	0.17±0.17	0.06±0.12	0.30±0.15	0.07±0.10	0.31±0.16	0.03±0.06

UDVA: Uncorrected distance visual acuity; CDVA: corrected distance visual acuity; UNVA: uncorrected near visual acuity; CNVA: distance corrected near visual acuity; UIVA: Uncorrected intermediate visual acuity; CIVA: distance corrected intermediate visual acuity

(CNVA) with the ETDRS Format Near Vision card at 40 cm, and uncorrected intermediate visual acuity (UIVA) and corrected intermediate visual acuity (CIVA) with the ETDRS card at 80 cm. Refractive status was recorded as in preoperative assessment. High-contrast (100%) and low-contrast (10%) visual acuities measured using ETDRS chart at 100 cm under 85 cd/m² luminance at 1-, 3-, and 6-month visits were also recorded. Any adverse experiences or complications observed by the investigator or reported by the patients were noted. Exclusion criteria were preexisting retinal disease or ocular pathology and previous ocular surgery. Patients with incomplete data were also excluded.

Study IOL

The Optiflex MOFNYA01 IOL (Figure 1) is a single-piece, 360° square-edge hydrophilic acrylic IOL with aberration-free aspheric optics. The IOL has an overall size of 12.5 mm and an optical size of 6 mm. The IOL is supplied in diopters of +5.0 to +30.0 D (with 0.5 D steps from +15.0 D to +25.0 D). It contains a unique covalently bonded patented natural chromophore, which contains the same UV-A blocking and violet-light filtering chromophore found in the human crystalline lens.

Statistical Analysis

Statistical analysis was performed using Statistical Package for Social Sciences version 21.0 (IBM Corp., Armonk, NY, USA) software. Frequency (N), mean (SD), and minimum and maximum values were reported for continuous variables. Frequency and percentage were displayed for categorical variables. All continuous variables were assessed by appropriate statistical tests for normality distribu-

tion. Statistical significance for efficacy variables following normal distribution was evaluated by paired t-test between preoperative mean value and mean value at postoperative 1-week and 1-, 3-, and 6-month follow-up. Statistical significance for efficacy variables not following normal distribution was evaluated by Wilcoxon signed-rank test between preoperative mean value and mean value at postoperative 1 week and 1-, 3-, and 6-month follow-up.

RESULTS

A total of 48 eyes of 48 patients with mean age of 66.84±9.72 years (range, 43–88 years) and equal distribution of both genders were included in this study.

Visual Acuity

Visual acuity results of the study group are summarized in Table 1.

Uncorrected Distance Visual Acuity (UDVA)

There is a statistically significant improvement ($p < 0.001$) in UDVA in all postoperative visits compared with the preoperative visits (Figure 2).

Corrected Distance Visual Acuity (CDVA)

A statistically significant improvement ($p < 0.001$) in CDVA was observed at every postoperative visit (Figure 2). At the 6-month visit, mean CDVA was 0.06±012 LogMAR, and there was a significant improvement of four lines on average from the preoperative visit.

Uncorrected Intermediate Visual Acuity (UIVA) and Corrected Intermediate Visual Acuity (CIVA)

There is a statistically significant improvement in UIVA ($p < 0.003$) and CIVA ($p < 0.000$) at 6-month follow-up visit compared with the 1-week follow-up visit (Figure 3).

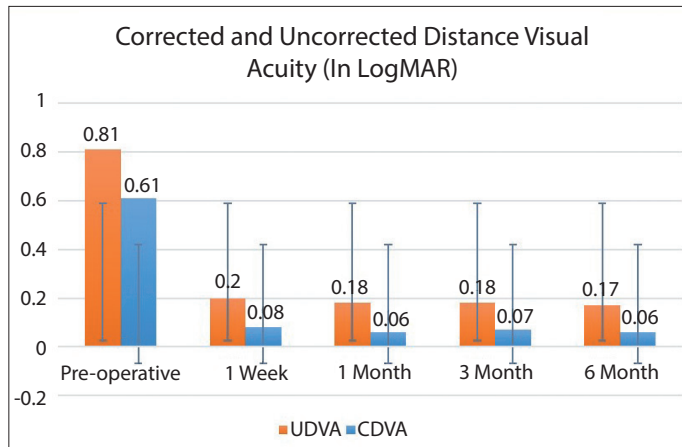


Figure 2. Re-ANOVA graph for uncorrected distance visual acuity (UDVA) and corrected distance visual acuity (CDVA), within group analysis n=48 eyes

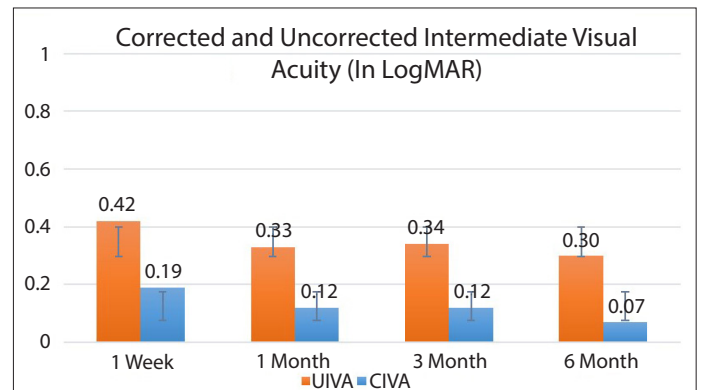


Figure 3. Re-ANOVA graph for uncorrected intermediate visual acuity (UIVA) and corrected intermediate visual acuity (CIVA), within group analysis n=48 eyes

Table 2. Mean spherical equivalent (diopters) (n=48) for the cohort

	Mean	Std. Deviation	Minimum	Maximum	p
Preoperative	-0.33	2.49	-5.13	4.00	
Postoperative 1 week	-0.11	0.68	-2.13	1.25	0.599
Postoperative 1 month	-0.19	0.60	-2.13	1.13	0.660
Postoperative 3 months	-0.12	0.61	-1.25	1.13	0.945
Postoperative 6 months	-0.15	0.64	-2.25	1.25	0.637

Uncorrected Near Visual Acuity (UNCA) and Corrected Near Visual Acuity (CNVA)

There was no statistically significant change from the 1-week follow-up ($p > 0.05$) in UNCA and CNVA mean at 1-, 3-, and 6-month follow-up compared with the 1-week follow-up visit (Figure 4).

Refraction

Mean Refractive Spherical Equivalent (MRSE)

There was no statistically significant change from the preoperative values ($p > 0.05$) in mean refractive spherical equivalent at 1-week and 1-, 3-, and 6-month follow-up.

Descriptive statistics of mean spherical equivalent preoperative and postoperative follow-up are presented in Table 2.

Contrast Sensitivity

Contrast sensitivity outcomes are shown in Table 3. High-contrast (100%) and low-contrast (10%) visual acuity were improved during follow-up visits ($p \leq 0.01$ and $p \leq 0.01$, respectively) through the follow-up period with a mean high-contrast score of 0.06 ± 0.08 LogMAR and low-contrast score of 0.29 ± 0.12 at the 6-month visit (Figure 5).

Safety Evaluation

There were no reported adverse events and intraoperative or postoperative complications associated with the study IOL that required additional intervention or treatment. We only observed diabetic retinopathy development in one of the patients 4 months after surgery.

DISCUSSION

Factors affecting the light path in the pseudophakic eyes are pupil diameter (natural/dilated papilla), optical material (hydrophilic/hydrophobic IOL), and IOL surface curvature (spherical/aspheric IOL) (9). It is obvious that perfection in visual functions can be achieved by changes in optical material and optical surface.

Patients implanted with hydrophilic IOL have been reported to be more susceptible to early onset of PCO (posterior capsular opacification), and increased rates have been observed, but PCO formation can be reduced and prevented by 360° square-edge optical design of the IOL (10-13). In contrast, hydrophilic IOLs have been reported to have superior visual function (or optical quality) due to the smaller size of chromatic aberrations (14). The parameters used to evaluate optical quality are visual acuity, contrast sensitivity, glare disability, night vision, HOAs and subjective surveys. Hydrophobic surface coating on hydrophilic optical material and square-edge design are selected in this study because of high optical quality. Published studies suggest that aspheric IOLs with a monofocal aberration-free design similar to that of the study IOL improve postoperative visual acuity measured simply as best-corrected visual acuity (BCVA). For example, in a study by von Sonnleithner C et al. (15), 157 eyes of 106 patients were included in the study. Twenty six eyes were implanted with aspheric Incise® IOL MJ14T (Bausch & Lomb, Rochester, N.Y., USA), and the control groups consisted of patients operated with 1.8-mm (coaxial MICS, Akreos MI60, 41 eyes), 2.2-mm (small-inci-

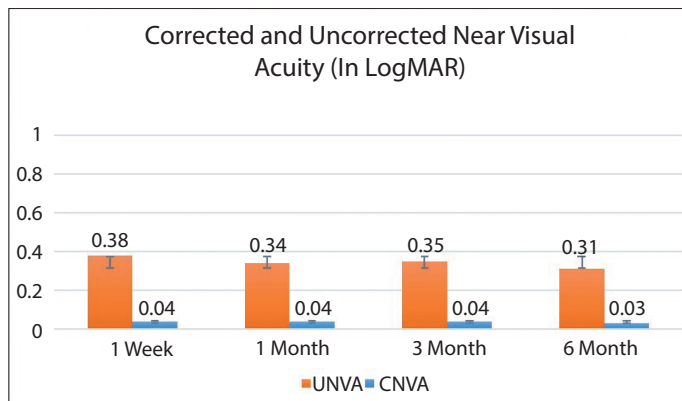


Figure 4. Re-ANOVA graph for uncorrected near visual acuity (UNVA) and corrected near visual acuity (CNVA), within group analysis n=48 eyes

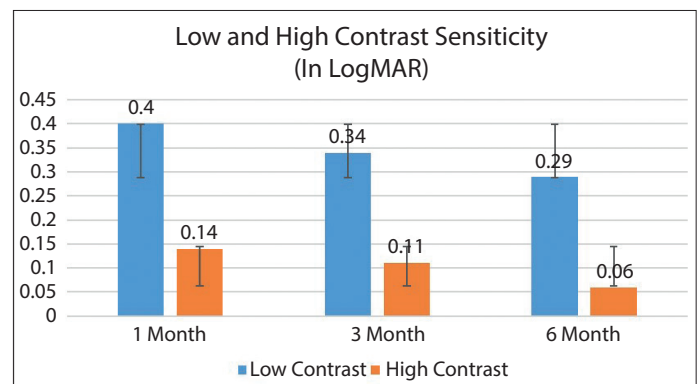


Figure 5. Re-ANOVA for postoperative high contrast (100%) visual acuity and low contrast (10%) visual acuity, within groups analysis n=48 eyes

Table 2. Mean spherical equivalent (diopters) (n=48) for the cohort

		Mean	Std. Deviation	Minimum	Maximum
Postoperative 1 month contrast sensitivity	Low*	0.40	0.10	0.2	0.6
	High*	0.14	0.09	0	0.3
Postoperative 3 months contrast sensitivity	Low*	0.34	0.12	0.1	0.5
	High*	0.11	0.09	0	0.3
Postoperative 6 months contrast sensitivity	Low*	0.29	0.12	0	0.5
	High*	0.06	0.08	0	0.3

*with ETDRS chart at 100 cm, under 85 cd/m² luminance

sion cataract surgery, Tecnis ZCB00, 44 eyes), and 2.2-mm (small-incision cataract surgery, CT Asphina, 46 eyes) coaxial phacoemulsification with implantation of an aspheric IOL. At 6 months postoperative, BCVA in all groups had significantly improved from baseline (no intragroup difference). More specifically, the new aspheric Incise IOL group achieved a mean BCVA of 0.05 LogMAR at 6 months postoperative – a result similar to the CDVA of 0.06 achieved in the current study. However, the aspheric construction of the optical surface curvature is perhaps as important as the material in increasing the optical quality. Because spherical aberration of the natural lens changes in life from negative to positive values and hence impairs optical quality, implanting an aspheric IOL based on the young natural lenses' asphericity parameters, inducing negative, neutral, or individual spherical aberration, should improve the optical quality (16).

It has been shown that the well-focused aspheric IOL has been shown to increase the optical quality compared with the spherical IOL in the simulated eye model (17). Aspheric monofocal IOL implantation resulted in less ocular spherical aberration and fewer ocular HOAs than spherical IOLs (18, 19). This might explain the better contrast sensitivity in patients with aspheric IOLs. As a matter of fact, very good contrast sensitivity results were obtained with the IOL used in the study. In the current study, contrast sensitivity outcome was considered satisfactory, as low-contrast (10%) visual acuity remained stable across the postoperative period with a mean of 0.29 ± 0.12 LogMAR at the last visit.

Additionally, in cases of aspheric IOL implantation, ocular vertical coma may be a major HOA associated with better near visual acuity (20). It has long been recognized that the pseudophakic eye implanted with a monofocal IOL has better near acuity than expected. This better-than-expected outcome has been attributed to the depth of field associated with the pseudophakic eye. Factors affecting the depth of field are pupil size, anterior chamber depth, and corneal power (21). We also reported that UNVA was better than expected with MOFYNA 01 IOL in this study. Yamauchi et al. (22) published a paper retrospectively comparing the visual performance of multifocal IOLs (Tecnis® ZMA00: 32 patients; ZMB00: 14 patients) and monofocal IOLs (Tecnis® ZA9003: 47 patients; ZCB00: 38 patients) made of the same material. In this study, at 14 weeks postoperatively, UNVA was 0.54 LogMAR and CNVA was 0.00 LogMAR with monofocal aspheric IOLs, similar to our study, 0.31 and 0.03 LogMAR, respectively. Yamauchi et al. (22) also reported NVA was significantly better in the multifocal group, whereas CIVA and CNVA were better in the monofocal group.

Another feature of the IOL that we used in the study is natural yellow chromophore. At the beginning, theories that blue light could be related to the pathogenesis of age-related macular degeneration (AMD) have led to the use of yellow-tinted IOLs in cataract surgery to filter short wavelength light. In spite of the potential benefits, some concerns have been raised. The potential advantages of the blue-light filtering IOLs are that they could better mimic the conditions of phakia and therefore be more protective for the retina in decreasing the incidence of AMD. However, the potential disadvantages are that blue-light filtering could negatively affect scotopic vision and circadian rhythms in older patients (23). Subsequent studies and information have not proven that blue-light-blocking lenses provide protection to AMD, visual impairment, or

significant harmful effects in the circadian rhythm (24). There is also no evidence that blue-light filtering IOLs are superior to UV filtered ones (25, 26). Since the study period was limited to 6 months and there were no control groups, no comments were made on the positive or negative effects of blue filter.

Apart from visual quality, visual side effects, such as glare, halo, and chromatic aberrations, are also important as the second component of visual function. Materials with high refractive index, especially in the hydrophilic acrylic lens group, are considered to have low Abbe ratio or significant chromatic aberrations (27). In other words, a thin IOL with a high refractive index does not only have a high reflectance property but also exhibits poor chromatic aberration properties. Since the IOL used in our study had a low refractive index, no visual adverse effects were observed in any patient. This is probably related to the IOL design as well as the low refractive index.

CONCLUSION

The Optiflex MO/FNYA01 IOL was safely implanted without any complications and allowed for improved visual acuity outcomes in patients who underwent cataract surgery while preserving contrast sensitivity over a 6-month follow-up period. With Optiflex MO/FNYA01 IOL, surgical performance and early visual and predictability outcomes were satisfactory; however, further studies with longer follow-up and larger case series are needed.

Ethics Committee Approval: Ethics committee approval was received for this study from the Ethics Committee of Bakırköy Dr. Sadi Konuk Research and Training Hospital (2015/17/05).

Informed Consent: Informed consent was not taken from patients due to the retrospective nature of the study.

Peer-review: Externally peer-reviewed.

Author Contributions: Concept - U.Y., E.Ç.; Design - U.Y., E.Ç.; Supervision - U.Y., E.Ç., U.O., S.K.; Resources - U.Y., E.Ç.; Materials - U.Y., E.Ç.; Data Collection and/or Processing - U.Y., E.Ç.; Analysis and/or Interpretation - U.Y., E.Ç., U.O.; Literature Search - E.Ç., S.K.; Writing Manuscript - U.Y., U.O.; Critical Review - U.O., S.K.

Conflict of Interest: The authors have no conflict of interest to declare.

Financial Disclosure: The authors declared that this study has received no financial support.

Etik Komite Onayı: Bu çalışma için etik komite onayı Bakırköy Dr. Sadi Konuk Eğitim ve Araştırma Hastanesi Etik Kurulu'ndan alınmıştır.

Hasta Onamı: Çalışmanın retrospektif tasarımından dolayı hasta onamı alınamamıştır.

Hakem Değerlendirmesi: Dış bağımsız.

Yazar Katkıları: Fikir - U.Y., E.Ç.; Tasarım - U.Y., E.Ç.; Denetleme - U.Y., E.Ç., U.O., S.K.; Kaynaklar - U.Y., E.Ç.; Malzemeler - U.Y., E.Ç.; Veri Toplanması ve/veya İşlemesi - U.Y., E.Ç.; Analiz ve/veya Yorum - U.Y., E.Ç., U.O.; Literatür Taraması - E.Ç., S.K.; Yazıyı Yazan - U.Y., U.O.; Eleştirel İnceleme - U.O., S.K.

Çıkar Çatışması: Yazarların beyan edecek çıkar çatışması yoktur.

Finansal Destek: Yazarlar bu çalışma için finansal destek almadıklarını beyan etmişlerdir.

REFERENCES

- Schuster AK, Tesarz J, Vossmerbaeumer U. The impact on vision of aspheric to spherical monofocal intraocular lenses in cataract surgery: a systematic review with metaanalysis. *Ophthalmology* 2013; 120: 2166-75. [\[CrossRef\]](#)
- Kretz F, Tandogan T, Khoramnia R, Auffarth GU. High order aberration and straylight evaluation after cataract surgery with implantation of an aspheric, aberration correcting monofocal intraocular lens. *Int J Ophthalmol* 2015; 8: 736-41.
- Sandoval HP, Fernández de Castro LE, Vroman DT, Solomon KD. Comparison of visual outcomes, photopic contrast sensitivity, wavefront analysis, and patient satisfaction following cataract extraction and IOL implantation: aspheric vs spherical acrylic lenses. *Eye (Lond)* 2008; 22: 1469-75. [\[CrossRef\]](#)
- Denoyer A, Denoyer L, Halfon J, Majzoub S, Pisella PJ. Comparative study of aspheric intraocular lenses with negative spherical aberration or no aberration. *J Cataract Refract Surg* 2009; 35: 496-503. [\[CrossRef\]](#)
- Trueb PR, Albach C, Montés-Micó R, Ferrer-Blasco T. Visual acuity and contrast sensitivity in eyes implanted with aspheric and spherical intraocular lenses. *Ophthalmology* 2009; 116: 890-5. [\[CrossRef\]](#)
- Alió JL, Pi-ero DP, Ortiz D, Montalbán R. Clinical outcomes and postoperative intraocular 'optical quality with a microincision aberration-free aspheric intraocular lens. *J Cataract Refract Surg* 2009; 35: 1548-54. [\[CrossRef\]](#)
- Lee KM, Park SH, Joo CK. Comparison of clinical outcomes with three different aspheric intraocular lenses. *Acta Ophthalmol* 2011; 89: 40-6. [\[CrossRef\]](#)
- Nochez Y, Majzoub S, Pisella PJ. Effect of interaction of macroaberrations and scattered light on objective quality of vision in pseudophakic eyes with aspheric monofocal intraocular lenses. *J Cataract Refract Surg* 2012; 38: 633-40. [\[CrossRef\]](#)
- Tang Y, Song H, Chen J, Tang X. Comparison of pseudophakic retinal straylight in spherical/aspherical and hydrophobic/hydrophilic intraocular lens. *Int J Ophthalmol* 2015; 8: 1146-50.
- Kugelberg M, Wejde G, Jayaram H, Zetterström C. Two-year follow-up of posterior capsule opacification after implantation of a hydrophilic or hydrophobic acrylic intraocular lens. *Acta Ophthalmol* 2008; 86: 533-6. [\[CrossRef\]](#)
- Cullin F, Busch T, Lundström M. Economic considerations related to choice of intraocular lens (IOL) and posterior capsule opacification frequency - a comparison of three different IOLs. *Acta Ophthalmol* 2014; 92: 179-83. [\[CrossRef\]](#)
- Sharon Y, Livny E, Mimouni M, Weinberger D, Bahar I. Laser capsulotomy following cataract surgery: Comparing time to capsulotomy with implantation of two broadly used intraocular lenses. *Indian J Ophthalmol* 2017; 65: 144-7. [\[CrossRef\]](#)
- Findl O, Buehl W, Bauer P, Sycha T. Interventions for preventing posterior capsule opacification. *Cochrane Database Syst Rev* 2010; 17: CD003738. [\[CrossRef\]](#)
- Vinas M, Dorronsoro C, Garzon N, Poyales F, Marcos S. In vivo subjective and objective longitudinal chromatic aberration after bilateral implantation of the same design of hydrophobic and hydrophilic intraocular lenses. *J Cataract Refract Surg* 2015; 41: 2115-24. [\[CrossRef\]](#)
- von Sonnleithner C, Bergholz R, Gonnermann J, Klamann MK, Torun N, Bertelmann E. Clinical Results and Higher-Order Aberrations after 1.4-mm Biaxial Cataract Surgery and Implantation of a New Aspheric Intraocular Lens. *Ophthalmic Res* 2015; 53: 8-14. [\[CrossRef\]](#)
- Kohnen T, Klaproth OK. Aspheric intraocular lenses. *Ophthalmologie* 2008; 105: 234-40. [\[CrossRef\]](#)
- Nan L, Tang X, Liu YJ. Depth of focus in spherical and aspheric intraocular lenses. *Zhonghua Yan Ke Za Zhi* 2012; 48: 137-41.
- Schuster AK, Tesarz J, Vossmerbaeumer U. Ocular wavefront analysis of aspheric compared with spherical monofocal intraocular lenses in cataract surgery: Systematic review with metaanalysis. *J Cataract Refract Surg* 2015; 41: 1088-97. [\[CrossRef\]](#)
- Schuster AK, Tesarz J, Vossmerbaeumer U. The impact on vision of aspheric to spherical monofocal intraocular lenses in cataract surgery: a systematic review with meta-analysis. *Ophthalmology* 2013; 120: 2166-75. [\[CrossRef\]](#)
- Song IS, Kim MJ, Yoon SY, Kim JY, Tchah H. Higher-order aberrations associated with better near visual acuity in eyes with aspheric monofocal IOLs. *J Refract Surg* 2014; 30: 442-6. [\[CrossRef\]](#)
- Barišić A, Patel S, Gabric N, Feinbaum CG. The clinical depth of field achievable with trifocal and monofocal intraocular lenses: theoretical considerations and proof of concept clinical results. *Graefes Arch Clin Exp Ophthalmol* 2017; 255: 367-73. [\[CrossRef\]](#)
- Yamauchi T, Tabuchi H, Takase K, Ohsugi H, Ohara Z, Kiuchi Y. Comparison of Visual Performance of Multifocal Intraocular Lenses with Same Material Monofocal Intraocular Lenses. *PLoS One* 2013 28; 8: e68236. [\[CrossRef\]](#)
- Yang H, Afshari NA. The yellow intraocular lens and the natural ageing lens. *Curr Opin Ophthalmol* 2014; 25: 40-3. [\[CrossRef\]](#)
- Lai E, Levine B, Ciralsky J. Ultraviolet-blocking intraocular lenses: fact or fiction. *Curr Opin Ophthalmol* 2014; 25: 35-9. [\[CrossRef\]](#)
- Li X, Kelly D, Nolan JM, Dennison JL, Beatty S. The evidence informing the surgeon's selection of intraocular lens on the basis of light transmittance properties. *Eye* 2017; 31: 258-72. [\[CrossRef\]](#)
- Downes SM. Ultraviolet or blue-filtering intraocular lenses: what is the evidence? *Eye* 2016; 30: 215-21. [\[CrossRef\]](#)
- Chang DH, Rocha KM. Intraocular lens optics and aberrations. *Curr Opin Ophthalmol* 2016; 27: 298-303. [\[CrossRef\]](#)