



Self-Expandable Metal Stent Application as Bridging Therapy in Refractory Esophageal Variceal Bleeding

Bülent Çolak¹, Eylem Karatay², Harun Erdal³, Mahir Keleş¹, İbrahim Doğan³, Selahattin Ünal³

¹Clinic of Internal Medicine, Kilis State Hospital, Kilis, Turkey

²Clinic of Gastroenterology, Gaziosmanpaşa Taksim Training and Research Hospital, İstanbul, Turkey

³Department of Gastroenterology, Gazi University School of Medicine, Ankara, Turkey

ABSTRACT

Esophageal variceal bleeding is a serious complication of portal hypertension in cirrhotic patients. Current treatment approach consists of band ligation and sclerotherapy. More than 10% of variceal bleedings are refractory to standard treatments and have a higher mortality rate. In this study, we aimed to share our experiences regarding covered self-expanding metal stent (SEMS) as a bridging therapy to permanent treatments, which decrease portal blood pressure, such as TIPS and surgery in two refractory variceal bleeding patients who were referred to our hospital with a past history of multiple band ligations to esophageal varices. (*JAREM 2016; 6: 119-21*)

Keywords: Esophageal variceal bleeding, self-expanding metal stent, band ligation

INTRODUCTION

Esophageal variceal bleeding is a serious complication of portal hypertension in cirrhotic patients. The current treatment approach consists of band ligation and sclerotherapy. More than 10% of variceal bleedings are refractory to standard treatments; therefore, they have a higher mortality rate (1).

Success rate of balloon tamponade in short-term variceal bleeding is between 50%–95%. Serious complications of balloon tamponade are aspiration pneumonia, airway obstruction, and huge esophageal ulceration (2). The placement of self-expanding metal stent (SEMS) has been used as a new rescue therapy since 2003. Fabienne et al. (2) used the placement of fully-covered SEMS as an alternative therapy to balloon tamponade in acute refractory variceal bleedings. Results of four big studies that have reported lesser complication and higher bleeding control rates in acute variceal bleeding are encouraging. According to these results, covered SEMS can be considered as a treatment option for refractory variceal bleedings (2). With the current study, we aim to demonstrate that the placement of covered SEMS can be used as a bridging therapy to permanent treatments such as TIPS and surgery, which decrease portal blood pressure. In our study, two refractory variceal bleeding patients had a past history of multiple band ligations to esophageal varices due to liver cirrhosis and portal vein thrombosis.

CASE PRESENTATION

A 70-year-old male patient was admitted to the emergency service department with hematemesis. Esophageal varices had been revealed with esophagogastroduodenoscopy in 2004. Further investigations revealed portal vein thrombosis. Multiple band ligations had been performed because of recurrent variceal bleeding.

Chronic obstructive pulmonary disease, deep vein thrombosis, and MTHFR gene mutation were the concomitant diseases. The patient was using propranolol to prevent variceal bleeding.

Laboratory examination results were as follows: Hb, 6.5 gr/dL; WBC, 5000/mm³; platelet, 34000/mm³; AST, 19 IU/L; ALT, 10 IU/L; ALP, 52 IU/L; GGT, 12 IU/L; total Bil, 1.3 mg/dL; Alb, 2.4 gr/dL; PT, 13 s; INR, 1.1.

Esophagogastroduodenoscopy revealed 3 colons of grade 2–3 esophageal varices in the distal esophagus. Band ligation was performed. Hematemesis began 72 h after band ligation. In control endoscopy, active bleeding from an ulcerated varice, which had been subjected to band ligation, was seen. But the varice was not suitable for ligation. Therefore, SX-Ella Danis SEMS (ELLA-CS, Hradec Kralove, Czech Republic) variceal stent was placed, and the bleeding stopped immediately. Covered SEMS was removed with a special extractor (PX-Ella Extractor, ELLA-CS) on the 14th day after placement. No complications were observed. Distal splenorenal shunt surgery was performed after stent removal to decrease portal pressure. Figures 1 and 2 demonstrate endoscopic and fluoroscopic images of the variceal stent. Figure 3 demonstrates distal esophageal varices after stent removal.

A 44-year-old female patient was admitted to the emergency service department with massive hematemesis. She had been followed up for portal vein thrombosis since 2009, and she had been treated with multiple band ligations. The latest band ligation had been performed a month ago. She was using insulin for diabetes mellitus, a concomitant disease. She was using propranolol 40 mg/day. Laboratory examination results were as follows: Hb, 7.4 gr/dL; WBC, 5400/mm³; platelet, 55600/mm³; PT, 17 s; INR, 1.52; AST, 29 IU/L; ALT, 15 IU/L; total Bil, 0.86 mg/dL; Alb, 2.3 gr/dL; ALP, 83 IU/L; GGT, 16 IU/L.



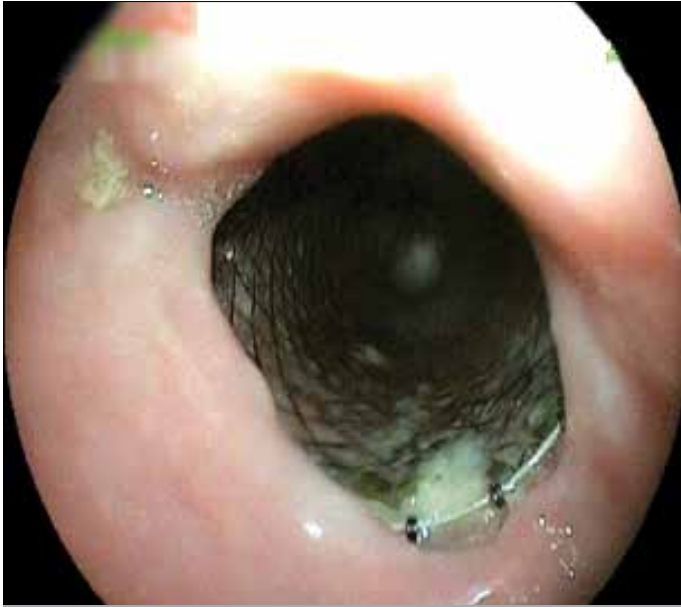

Figure 1. Endoscopic and fluoroscopic images of the variceal stent

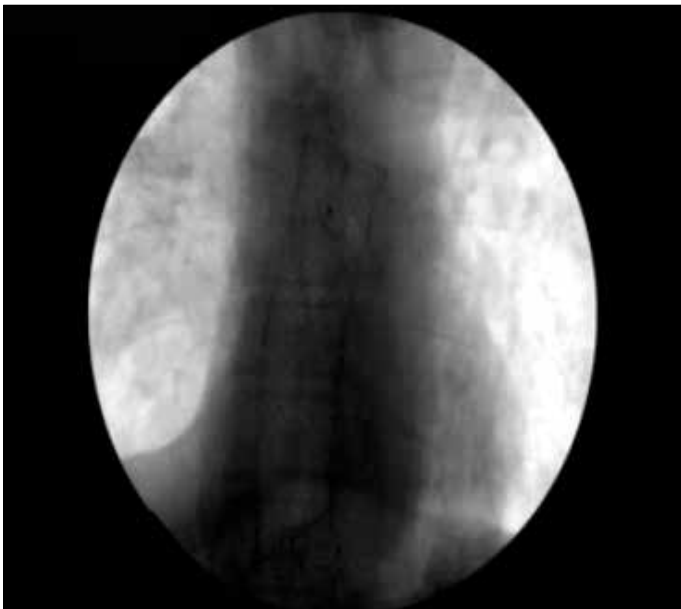


Figure 2. Endoscopic and fluoroscopic images of the variceal stent

An active bleeding ulcer on a varice colon that had been ligated was revealed at the distal esophagus during esophagogastroduodenoscopy. Band ligation was not suitable because of sclerosis secondary to recurrence band ligations. Four packs of erythrocyte suspension transfusion were required. SX-Ella Danis esophageal variceal stent was placed. Stent placement at distal esophagus was demonstrated on fluoroscopy. Blood transfusion was not required after the procedure.

Partial thrombus in the main portal vein lying to the left and right portal veins, tense ascites, and pleural effusion were demonstrated on CT Angiography. Transjugular portosystemic intrahepatic shunt (TIPS) was performed on the 13th day after stent placement. The portal venous pressure was 37 mmHg

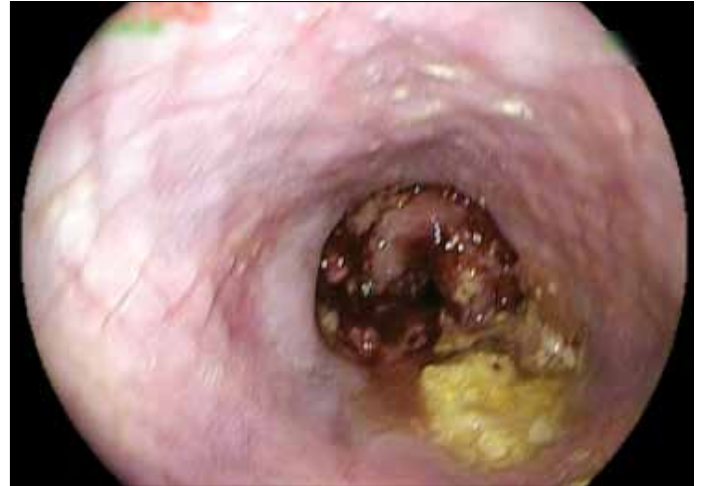

Figure 3. Distal esophageal varices after stent removal

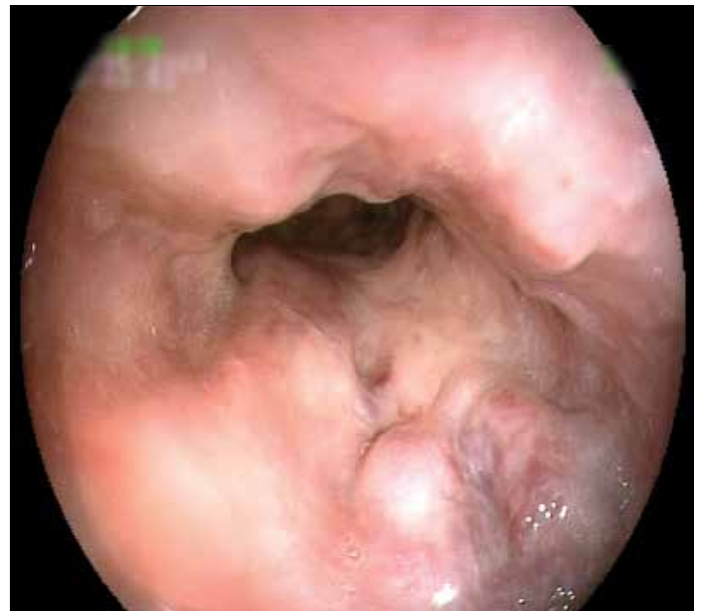


Figure 4. Endoscopic images before stent placement

before the TIPS procedure and 14 mmHg after the TIPS procedure.

Self-expanding metal stent was removed with the PX-Ella Extractor on the 14th day after placement. In control esophagogastroduodenoscopy, it was seen that all varices had completely shrunk. Endoscopic images before and after stent placement are shown in Figures 4 and 5.

DISCUSSION

The current treatment of acute variceal bleeding consists of a combination of hemodynamic stabilization, antibiotic prophylaxis, pharmacological agents such as terlipressin and somatostatin or their analogs, and endoscopic treatments.

Band ligation or sclerotherapy must be performed after the patient stabilizes. Recurrent bleeding occurs in 15%–20% of patients in the early period (first 5 days) because of endoscopic and pharmacological treatment failure. Mortality rate in these patients

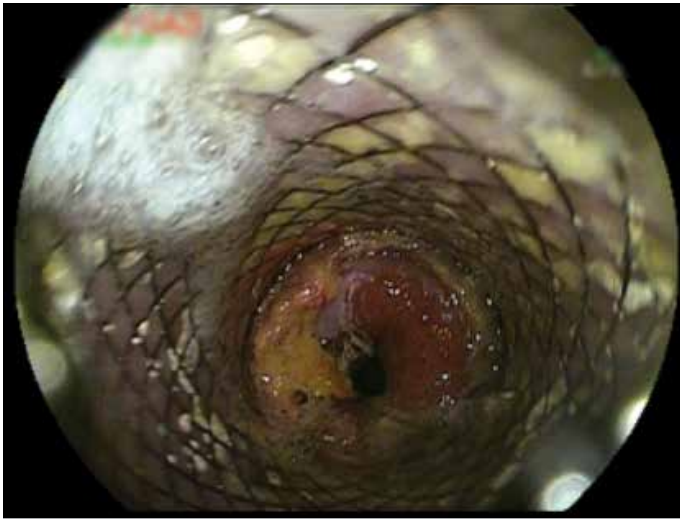

Figure 5. Endoscopic images after stent placement

is 30%–50% in different series, which is considerably high (3). If excessive bleeding occurs after endoscopic and pharmacological treatment failure, balloon tamponade is generally used until permanent treatments, such as TIPS or shunt surgery, are performed. SEMS, with a minor complication rate, is an alternative method to balloon tamponade as a bridging therapy. Wright et al. (4) successfully performed stent placement for 10 patients with refractory variceal bleeding. Patients' disease etiologies were cirrhosis secondary to Hepatitis C and alcohol and primary biliary cirrhosis.

Balloon tamponade is generally used until permanent treatments, such as TIPS or shunt surgery, are performed. SEMS, with a minor complication rate, is an alternative method to balloon tamponade as a bridging therapy. Wright et al. (4) successfully performed stent placement for 10 patients with refractory variceal bleeding. Patients' disease etiologies were cirrhosis secondary to Hepatitis C and alcohol and primary biliary cirrhosis.

CONCLUSION

We believe that our cases are of particular importance for the following reasons. First, we had patients with a different etiology (chronic portal vein thrombosis). Second, we successfully performed SEMS as a bridging therapy to permanent treatments such as TIPS and shunt surgery to decrease portal vein pressure. Furthermore, we believe that, because of SEMS, developed granulation tissue in esophageal mucosa play an important role in preventing new varice formation.

Informed Consent: Written and verbal informed consent was obtained from the parents of the patients who participated in this case.

Peer-review: Externally peer-reviewed.

Author Contributions: Concept - E.K., B.Ç.; Design - H.E., M.K.; Supervision - S.Ü., İ.D.

Conflict of Interest: No conflict of interest was declared by the authors.

Financial Disclosure: The authors declared that this study has received no financial support.

REFERENCES

1. Dechene A, El Fouly AH, Bechmann LP, Jochum C, Saner FH, Gerken G, et al. Acute Management of Refractory Variceal Bleeding in Liver Cirrhosis by Self-Expanding Metal Stents. *Digestion* 2012; 85: 185-91. [\[CrossRef\]](#)
2. Fabienne CF, Kistler W, Stenz V, Gubler C. Treatment of Esophageal Variceal Hemorrhage with Self- Expanding Metal Stents as a Rescue Maneuver in a Swiss Multicentric Cohort. *Case Rep Gastroenterol* 2013; 7: 97-105. [\[CrossRef\]](#)
3. D'Amico M, Berzigotti A, Garcia-Pagan JC. Refractory Acute Variceal Bleeding: Whatto Do Next? *Clin Liver Dis* 2010; 14: 297-305. [\[CrossRef\]](#)
4. Wright G, Lewis H, Hogan B, Burroughs A, Patch D, O'Beirne J. A Self-expanding metal stent for complicated variceal hemorrhage: experince a single center. *Gastrointestian Endoscopy* 2010; 71: 71-8. [\[CrossRef\]](#)