



A Rare Cause of Acute Abdomen in Children: Omental Infarction Due to Segmental Omental Torsion

Çocuklarda Akut Batının Nadir Bir Nedeni: Segmental Omentum Torsiyonuna Bağlı Omental İnfarktüs

Ahmet Ali Tuncer¹, Nadire Tuncer², Salih Çetinkuşun¹

¹Department of Pediatric Surgery, Afyon Kocatepe University School of Medicine, Afyonkarahisar, Turkey

²Clinic of Gynecology, Yüksekova State Hospital, Hakkari, Turkey

Cite this article as: Tuncer AA, Tuncer N, Çetinkuşun S. A Rare Cause of Acute Abdomen in Children; Omental Infarction Due to Segmental Omental Torsion. JAREM 2017; 7: 161-2.

ABSTRACT

Omental torsion is a rare cause of acute abdomen and is often confused with appendicitis because of physical examination findings that suggest appendicitis. Here we present a case of an 11-year-old girl with omental torsion who was medically treated. This study aimed to create awareness for omental infarction and help avoid unnecessary surgical procedures for medically treatable pathologies.

Keywords: Acute abdomen, omental torsion, child, ultrasound, computed tomography

ÖZ

Omentum torsiyonu akut karının nadir bir nedenidir. Apandisit taklit eden fizik muayene bulgularından ötürü sıklıkla akut apandisit ile karıştırılmaktadır. Bu yüzden omental torsiyonu olan ve medikal olarak tedavi edilen 11 yaşında bir kız olgu sunulmuştur. Bu makale oldukça nadir görülen omentum torsiyonunun farkındalığını artırmak ve medikal olarak tedavi edilebilen bu patoloji için yapılan gereksiz cerrahiye önlemek amacıyla yazılmıştır.

Anahtar kelimeler: Akut karın, omentum torsiyonu, çocuk, ultrason, bilgisayarlı tomografi

INTRODUCTION

Omental torsion is a rare cause of acute abdomen. Since its first description in 1896, approximately 300 cases of omental torsion have been reported. Patients with omental torsion comprise 85% of adult patients and 15% of pediatric patients (1). Omental torsion is often confused with appendicitis because of physical examination findings that suggest appendicitis. Diagnosis leads to confusion, and omental torsion is frequently observed in patients who underwent surgery with a diagnosis of appendicitis if the normal appearing appendix vermiformis is seen during exploration (2). This study aimed to create awareness for omental torsion and help avoid unnecessary surgical procedures for medically treatable pathologies.

CASE PRESENTATION

An 11-year-old girl with abdominal pain persisting for 1 day admitted to the emergency service. The patient was overweight (body weight, 60 kg; height, 140 cm; and body mass index, 28.5 kg/m²). Physical examination revealed tenderness in the right lower quadrant and right lateral side of the umbilicus. Laboratory test results revealed high white blood cell counts (10.15 mm³), high C-reactive protein levels (25.8 mg/dL), and biochemical value changes (sodium, 133 mmol/L; chloride, 98 mmol/L; lactate dehydrogenase, 339 U/L; and alkaline phosphatase, 262 U/L). Contrast-enhanced computed tomography (CT) revealed 51×25-mm-sized hyperdense fat tissues anterior to the ascending colon and cecum, which were compatible with an omental infarction due to segmental omental torsion (Figure 1). The patient was hospitalized in the pediatric surgery clinic of Yüksekova State Hospital. Written informed consent

was obtained from patients' parents who participated in this study. Oral intake was discontinued. Intravenous fluid support, ampicillin-sulbactam (Alfasid iv flk; Fako, İstanbul, Turkey), and metronidazole (Metrocel Biofleks 0.5%; Osel, İstanbul, Turkey) were administered. Abdominal ultrasound (US) and physical examinations were performed daily (Figure 2). Abdominal pain was relieved on the second day of hospitalization. On the third day of hospitalization, oral feeding was initiated. Infarction of fatty tissue decreased minimally in US made 5 days of hospitalization. The patient was discharged after prescribing antibiotics and antiinflammatory drugs for 10 days. Control abdominal US after 1 month revealed that omental infarction was completely resolved. The patient is being followed up for 18 months without any complications.

DISCUSSION

Omental infarction due to omental torsion is observed in 0.1% of children who undergo laparotomy for acute abdomen (3). Although the etiology remains unclear, omental torsion is implicated with predisposing factors such as anatomical variations, obesity, redundant omental veins, trauma, overeating, overexertion, sudden change in position, coughing straining, and presence of an inflammatory focus (3). Our patient was an obese patient. Omental infarcts may occur owing to torsion (idiopathic or secondary) or thrombosis (because of spontaneous or hypercoagulability) (4-6). In our case, because none of the leading causes such as coagulation disorder in blood test results and adhesion, hernia, or tumors in imaging procedures, omental infarction was considered to be associated with idiopathic torsion. Although often observed in adults, it also occurs in children with symptoms that suggest acute



abdomen. Omental torsion is more common in the right side than in the left side because right-sided omentum is longer and more mobile than left-sided omentum (7). Torsion on the right side can cause symptoms such as acute appendicitis, duodenal ulcer perforation, acute cholecystitis, cecal diverticulitis, and epiploic appendagitis (8). US and CT are useful imaging methods for making a diagnosis; however, these are usually detected during surgical procedures performed for another reasons. Omental infarction due to omental torsion can be treated through surgical excision or conservative management as in our case. Soobrah et al. (9) reviewed PubMed articles that were published between 1990 and 2010 and they reported that successful treatment of segmental omental infarction can be reached in 54 of 64 patients (83%) via conservative management. In 10 patients, the torsion segment was laparoscopically excised. In our case, symptoms completely resolved with a conservative treatment.

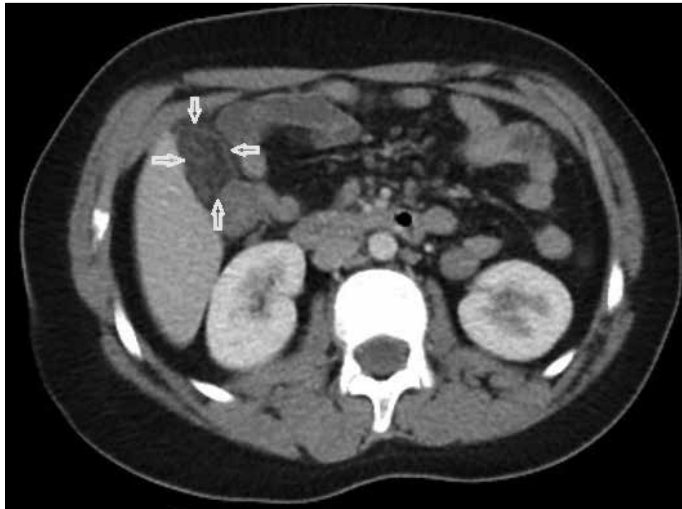


Figure 1. Contrast-enhanced computed tomography depicts an increased density and contamination that involves the right omentum (arrow)

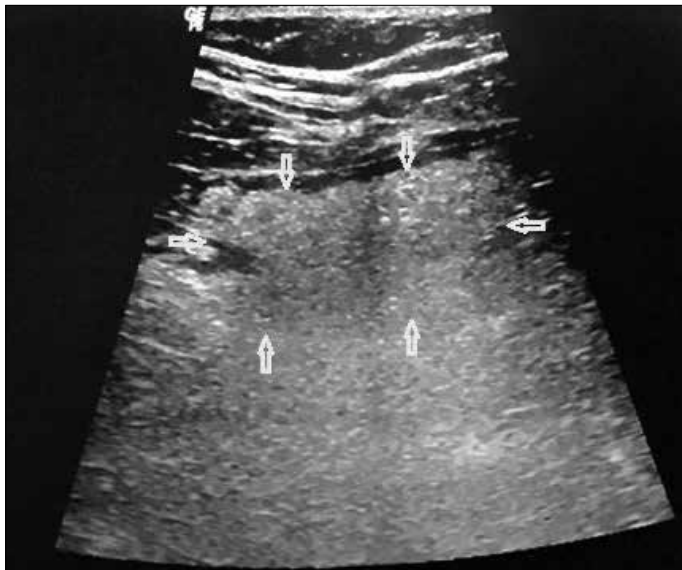

Figure 2. Ultrasonography revealed that a focal region of heterogeneous increased fat density (arrow)

CONCLUSION

As a result, omental infarction due to segmental omental torsion should be considered as a cause of acute abdomen, which can be self-limiting and conservatively treated. Diagnosis based on appropriate and qualified radiological examinations will prevent unnecessary surgeries.

Informed Consent: Written informed consent was obtained from patients' parents who participated in this study.

Peer-review: Externally peer-reviewed.

Author Contributions: Concept - A.A.T.; Design - A.A.T, N.T., S.Ç.; Supervision - S.Ç.; Resources - A.A.T., N.T.; Materials - A.A.T., N.T.; Data Collection and/or Processing - A.A.T., N.T.; Analysis and/or Interpretation - A.A.T., N.T., S.Ç.; Literature Search - A.A.T., S.Ç.; Writing Manuscript - A.A.T., N.T.

Acknowledgements: We would like to thank MD. Halil Boz for medical images.

Conflict of Interest: No conflict of interest was declared by the authors.

Financial Disclosure: The authors declared that this study has received no financial support.

Hasta Onamı: Yazılı hasta onamı bu çalışmaya katılan hastanın ailesinden alınmıştır.

Hakem Değerlendirmesi: Dış bağımsız.

Yazar Katkıları: Fikir - A.A.T.; Tasarım - A.A.T, N.T., S.Ç.; Denetleme - S.Ç.; Kaynaklar - A.A.T., N.T.; Malzemeler - A.A.T., N.T.; Veri Toplanması ve/veya İşlemesi - A.A.T., N.T.; Analiz ve/veya Yorum - A.A.T., N.T., S.Ç.; Literatür Taraması - A.A.T., S.Ç.; Yazıyı Yazan - A.A.T., N.T.

Teşekkür: Medikal görüntüler için Dr. Halil Boz'a teşekkür ederiz.

Çıkar Çatışması: Yazarlar çıkar çatışması bildirmemişlerdir.

Finansal Destek: Yazarlar bu çalışma için finansal destek almadıklarını beyan etmişlerdir.

REFERENCES

1. Hosseinpour M, Abdollahi A, Jazayeri H, Talari HR, Sadeghpour A. Omental torsion after repeated abdominal blunt trauma. Arch Trauma Res 2012; 1: 75-8. [CrossRef]
2. Oğuzkurt P, Kotiloğlu E, Tanyel FC, Hiçsönmez A. A primary omental torsion in a 6-year-old girl. J Pediatr Surg 1995; 30: 1700-1. [CrossRef]
3. Şencan A, Arslan O, Yılmaz Ö, Ayhan S, Mir E. A rare cause of acute abdominal pain: primary torsion of omentum majus. Turk J Gastroenterol 2002; 13: 122-4.
4. Stella DL, Schelleman TG. Segmental infarction of the omentum secondary to torsion: ultrasound and computed tomography diagnosis. Australas Radiol 2000; 44: 212-5. [CrossRef]
5. Cianci R, Filippone A, Basilico R, Storto ML. Idiopathic segmental infarction of the greater omentum diagnosed by unenhanced multidetector-row CT and treated successfully by laparoscopy. Emerg Radiol 2008; 15: 51-6. [CrossRef]
6. Battaglia L, Belli F, Vannelli A. Simultaneous idiopathic segmental infarction of the great omentum and acute appendicitis: a rare association. World J Emerg Surg 2008; 3: 30. [CrossRef]
7. Siu WT, Law BK, Tang CN, Chau CH, Li MK. Laparoscopic management of omental torsion secondary to an occult inguinal hernia. J Laparoendosc Adv Surg Tech A 2003; 13: 199-201. [CrossRef]
8. Naffaa LN, Shabb NS, Haddad MC. CT findings of omental torsion and infarction: case report and review of the literature. Clin Imaging 2003; 27: 116-8. [CrossRef]
9. Soobrah R, Badran M, Smith SG. Conservative management of segmental infarction of the greater omentum: a case report and review of literature. Case Rep Med 2010; 2010. pii: 765389. 2010 Sep 19.